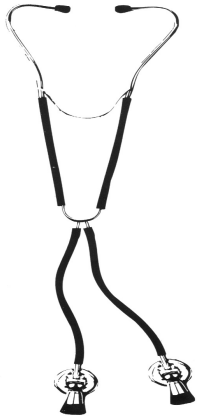


Maxilla to Mandible

Spring 2003



Dr. Gerald B. Wexler, B.Sc., D.D.S.
General Dentistry *including* **Temporomandibular Disorders and Orofacial Pain**
Diplomate, American Board of Orofacial Pain
2197 Riverside Drive, Suite 105, Ottawa, Ontario K1H 7X3
Phone (613) 731-2149 Fax (613) 731-0558 / www.drgeraldwexler.com

Topics In This Issue

| | |
|---|-----|
| TMJ Dysfunction with Malocclusion in Children and Adolescents..... | 2 |
| Factors Affecting Degeneration in Human TMJs..... | 2 |
| TM Disorders: Symptomatic Disc Displacement..... | 2,3 |
| Effect of Stabilization-Type Splints on the Asymmetry of Masseter Muscle Sites..... | 3 |
| Treatment of a Class II Malocclusion with Deep Overbite..... | 3 |
| TMD in Men..... | 3 |
| Predictors of Signs and Symptoms of TMD..... | 4 |
| MRI Findings of Internal Derangement in Temporomandibular Joints Without a Clinical Diagnosis of TMD..... | 4 |
| Human Leukocyte Antigens in Patients with Internal Derangement of the TMJ..... | 4 |
| Simplified Anterior Crossbite Correction Using a Bonded Compomer Biteplane..... | 4 |

Editorial

I am very pleased and proud to announce that we now have a new associate who has joined our practice.

This now affords me the opportunity to exclusively treat temporomandibular disorders and orofacial pain as well as major oral rehabilitation cases. Most of the general practice will now be managed by my associate.

We have noticed for a number of years that our waiting list has been growing both in number of patients and in the time they have to wait for a consultation and treatment. With this change we now have the facility to see your patients within two weeks rather than two months. Treatments can now be commenced without undue delay.



Our office has handled approximately 450 new patients a year for TMD and OFP. Of this number approximately 250 have undergone treatment. The treatments have included nightguards for bruxism, orthotics for snoring and sleep apnea, a therapy programs for jaw dysfunction, trigger point injections for myofascial pain problems, botox injections for chronic myospasm, pharmacological management of orofacial pains and headaches, and full mouth reconstruction and occlusal rehabilitation.

Our staff strives to excel in the maintenance of high standards of professionalism and work ethics with quality patient care and respect. We look forward to helping you with your patients' needs.

**TMJ Dysfunction with
Malocclusion in Children
and Adolescents**

Headache was the only symptom reported by this population of 4724 children ranging in age from 5 to 17 years old. The presence of one or more clinical signs was recorded in 25%, most of them mild.

The prevalence of signs increased during the developmental stages (from deciduous to permanent dentition) and was higher in females. TMD was associated with posterior crossbite (attributed to sliding of the mandible laterally), anterior open bite, Angle Class III malocclusion, and extreme maxillary overjet.

Poor dental health was believed to be a factor in the high prevalence of nonworking-side interferences (carious lesions, extracted molars). Dental wear was also associated with TMJ pain and muscle tenderness, especially in male cases. These patients frequently ground or clenched their teeth.

The authors recommend that patients with a morphological malocclusion should be treated orthodontically at an early age to correct the problem and be closely monitored for future problems.

Angle Orthodont 72(2): 146-154, 2002

Factors Affecting Degeneration in Human TMJs

TMJs were collected from 15 women and 38 men ranging in age from 15 to 92 years old at autopsy and analyzed for disc position and tissue damage. TMJ degeneration was mild to moderate up to 60 years of age and confined to the superficial articular tissue zones.

Age was the most important factor affecting degeneration, followed by loss of molar support, disc position, and load-bearing of the condyle and temporal component. The latter factor was more significant in older patients.

Lack of molar support contributed significantly more to the severity of tissue disintegration than the number of missing teeth. In those with abnormal disc positions, reduction of dental arch length also appeared to aggravate the loss of tissue.

Eur J Oral 110(2): 106-113, 2202

TM Disorders: Symptomatic Disc Displacement

The association with disc displacement (DD) was evaluated for bruxism, head-neck trauma, orthodontic treatment, and sociodemographic characteristics in 59 patients without myofascial pain. An association was found between DD (jaw pain and joint clicks) and clenching-grinding, which persisted when the patients were anxious or depressed.

A positive association was also noted between orthodontic treatment and DD, which also increased with anxiety or depression. Anxiety may activate the autonomic nervous system, which is believed to be associated with changes in nociception.

Although most of the patients in this study were younger and female, age and gender were not risk factors for DD. Further research is needed to determine if there is really a risk associated with orthodontic treatment and to include other factors, such as other diseases, types of trauma, and psychological factors.

J Oral Rehabil 29(5): 408-416, 2002

Effect of Stabilization-Type Splints on the Asymmetry of Masseter Muscle Sites

High-resolution ultrasonography was used to evaluate 24 patients with TMD. After splint insertion, a significant decrease in local maximal clenching-related muscle asymmetry for the antero-inferior masseter muscle was found, which suggests that splints can immediately reduce these asymmetries.

Additional clinical trials are needed to determine what role such factors as facial form, dental arch form, tooth contact pattern, bite force, and muscle use pattern play in the outcome of splint therapy. More research is also needed to validate ultrasonography as an accurate and reliable method for measuring local muscle thickness.

J Oral Rehabil 29(5): 447-451, 2002.

Treatment of a Class II Malocclusion with Deep Overbite

An 11 ½ year old girl with severe overbite and no obvious cause was treated to achieve a normal Class I occlusion, differential mandibular growth, clockwise mandibular rotation, and reduced skeletal overbite tendency. Because the patient was willing to cooperate, cervical headgear was used to treat growth modification and overbite correction, followed by fixed appliances and elastics.

This treatment approach resulted in better facial esthetics, reduced facial convexity while maintaining a normal lip profile, elimination of

maxillary arch length deficiency, and normal alignments without changing the arch form and intercanine width. A number of factors were key to achieving correction, including differential tooth movement with distalization of the maxillary dentition, anterior movement of the mandibular incisors, and maxillary first molar distal rotation around palatal roots.

Am J Orthod Dentofacial Orthop 121 (5): 531-537, 2002

TMD In Men

The prevalence of TMD signs and symptoms in this study of almost 28,000 males was similar to that of women or mixed samples of other workers. Masticatory muscle stiffness, TMJ sounds, headache, neck pain, bruxism and clenching were found in 17.8%, 14.3%, 7.2%, 13.5%, 8.4% and 9.9%, respectively.

TMJ noise was classified into noise during functioning, noise during maximum mouth opening, and past experience of noise, with incidence rates of 4.2%, 14.3%, and 3.9%, respectively. Stress occurred in almost 13%, past trauma history in 11%, and previous joint dislocation in under 3%.

Prior experience of a dislocated disc was found to be the most risky factor in TMD. Stress was related to limitations of mouth opening, and the experience of trauma was related to pain in the joint region. A clenching habit was found to be more harmful than bruxism.

J Oral Maxillofac Surg 60: 797-803, 2002.

Predictors of Signs

and Symptoms of TMD

In an attempt to predict what factors lead to TMD, subjects were followed up at age 27 to 35 years. The first exam occurred 20 years earlier. Possible predictors included tooth wear, deep bite recorded in childhood, TMJ clicking and bruxism.

Tooth wear and nocturnal tooth grinding were important for predicting TMJ clicking 20 years later. Whether these factors can be used to predict which patients will develop TMD still requires further study.

Acta Odontol Scand 60: 180-185, 2002.

MRI Findings of Internal Derangement in Temporomandibular Joints Without a Clinical Diagnosis of TMD

This study investigated the prevalence of internal derangement (ID) in TMJs for which there was no clinical diagnosis of temporomandibular disorder (TMD) and in those cases to determine if TMJ pain was associated with MRI findings of ID.

MRI diagnosis of ID was found in about 60% of the TMJs. About a third of the closed-mouth-related positions characterized by disc displacement were of the anterior type, while about 27% and 25% were anterolateral and anteromedial, respectively.

More pain was found with disc displacement without reduction. Thus, criteria used in clinical diagnosis is unreliable for predicting MRI diagnoses of TMD ID.

J Oral Rehabil 29(4): 516-522, 2002.

Human Leukocyte Antigens

in Patients with Internal Derangement of the TMJ

The prevalence of human leukocyte antigens (HLA) has been associated with certain types of arthritis, including reactive arthritis. Because the authors previously identified bacteria associated with this type of arthritis within the TMJ, they evaluated the frequency of HLA alleles in patients with TMD. A higher frequency of class I HLA alleles -A1, -A2, and -A3, HLA-B7, -B14, -B35, and -B44, as well as class II antigens -DR1 and -DR4 was found in these patients.

Thus, patients with a higher level of these alleles may be more susceptible to the development of internal derangement (ID) and have increased likelihood for the development of ID due to bacterial/infectious agents and the subsequent inflammation. Even a patient with no symptoms showing these alleles should be closely monitored.

J Oral Maxillofac Surg 60: 778-783, 2002.

Simplified Anterior Crossbite Correction Using a Bonded Compomer Biteplane

The several cases discussed here indicate that bonded compomer (resin-based composites made with glass filler particles and polyacid components) biteplanes can correct crossbite related to simple tipping of teeth. However, they cannot be used for patients with crowding or Class III malocclusion. If the biteplane is properly placed, the crossbite can usually be corrected within two weeks. A self-etching adhesive simplifies the bonding technique, while producing a durable and reliable bond. To complete the removal, a sharp carbide bur at slow speed should be used after the conventional high-speed, water-cooled bur is used.

J Clin Orthod 36: (6) 356-358, 2002